



PATIENT

Cooper Sumner

SPECIES

Canine

BREED

Puggle

SEX

MN

AGE

8 y

WEIGHT

30 lb

PRESENTING CLINICAL SIGNS

Grade 4/6 murmur, gallop sound. Received gabapentin and trazadone the night before the echo, and butorphanol and midazolam the morning of. Receives dexmedetomidine and butorphanol monthly for nail trims. Standing echo.

ECHOCARDIOGRAPHIC FINDINGS

2D, M-mode, and Doppler study.

Left atrial size is normal. The mitral valve leaflets are mildly thickened, and a mild jet of mitral regurgitation is present. Left ventricular dimensions are normal. Left ventricular systolic function is normal. The aorta and aortic valve appear normal, though trace aortic insufficiency is present. Right atrial and right ventricular dimensions are normal. The tricuspid valve is normal. The pulmonary artery and pulmonic valve appear normal. No shunting lesions are visualized. No pericardial effusion or cardiac masses are seen.

LA - 31.4 mm
LVIDd - 30.4 mm
LVIDs - 19.7 mm
FS - 35.2%
RA - 25.2 mm

INTERPRETED BY

Keith Blass, DVM, MS,
DACVIM (Cardiology)

IMAGING PERFORMED BY

Karen Ebersole, DVM,
DABVP

HOSPITAL NAME

Scanvet

REFERRING VET

Dr. Goodman

INVOICE

DATE

2/26/26

ASSESSMENT/RECOMMENDATIONS

Degenerative mitral valve disease - stage B1

This examination demonstrates mild regurgitation of blood across Cooper's mitral valve resulting from degenerative valve disease. The hemodynamic effects of the regurgitation also appear to be mild at present, as Cooper does not have secondary dilation of either of his left heart chambers, and his left ventricular systolic function is normal. As such, Cooper's current risk for the development of clinical signs secondary to his mitral valve disease, such as coughing, exercise intolerance, syncope, and labored breathing, appears to be low.

No therapy is recommended at this stage of disease, and there is no contraindication to giving dexmedetomidine if needed.

A recheck echocardiogram is recommended in 6 months.



PATIENT

Cooper Sumner

SPECIES

Canine

BREED

Puggle

SEX

MN

AGE

8 y

WEIGHT

30 lb

INTERPRETED BY

Keith Blass, DVM, MS,
DACVIM (Cardiology)

IMAGING PERFORMED BY

Karen Ebersole, DVM,
DABVP

HOSPITAL NAME

Scanvet

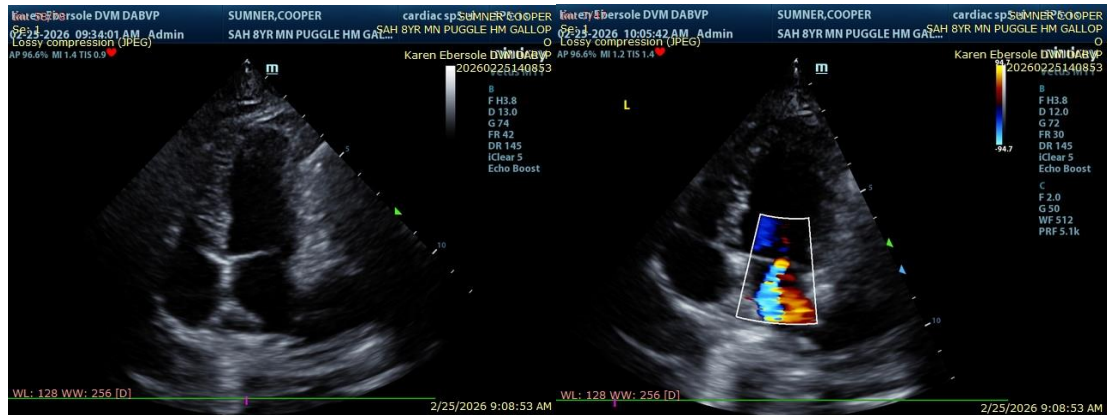
REFERRING VET

Dr. Goodman

INVOICE

DATE

2/26/26



The information and recommendations provided are based on the images presented by the referring veterinarian/sonographer. No evaluation can be communicated regarding pathology that was not visible in the image/video clips provided.

Thank you for this referral. If the clinical or image interpretation does not parallel your findings or if I can be of any further assistance please contact me.

Keith Blass, DVM, MS, DACVIM (Cardiology) info@SonoPath.com